Dermatopathology Slide Review Part 123

Paul K. Shitabata, M.D.
Dermatopathology Institute
Torrance, CA

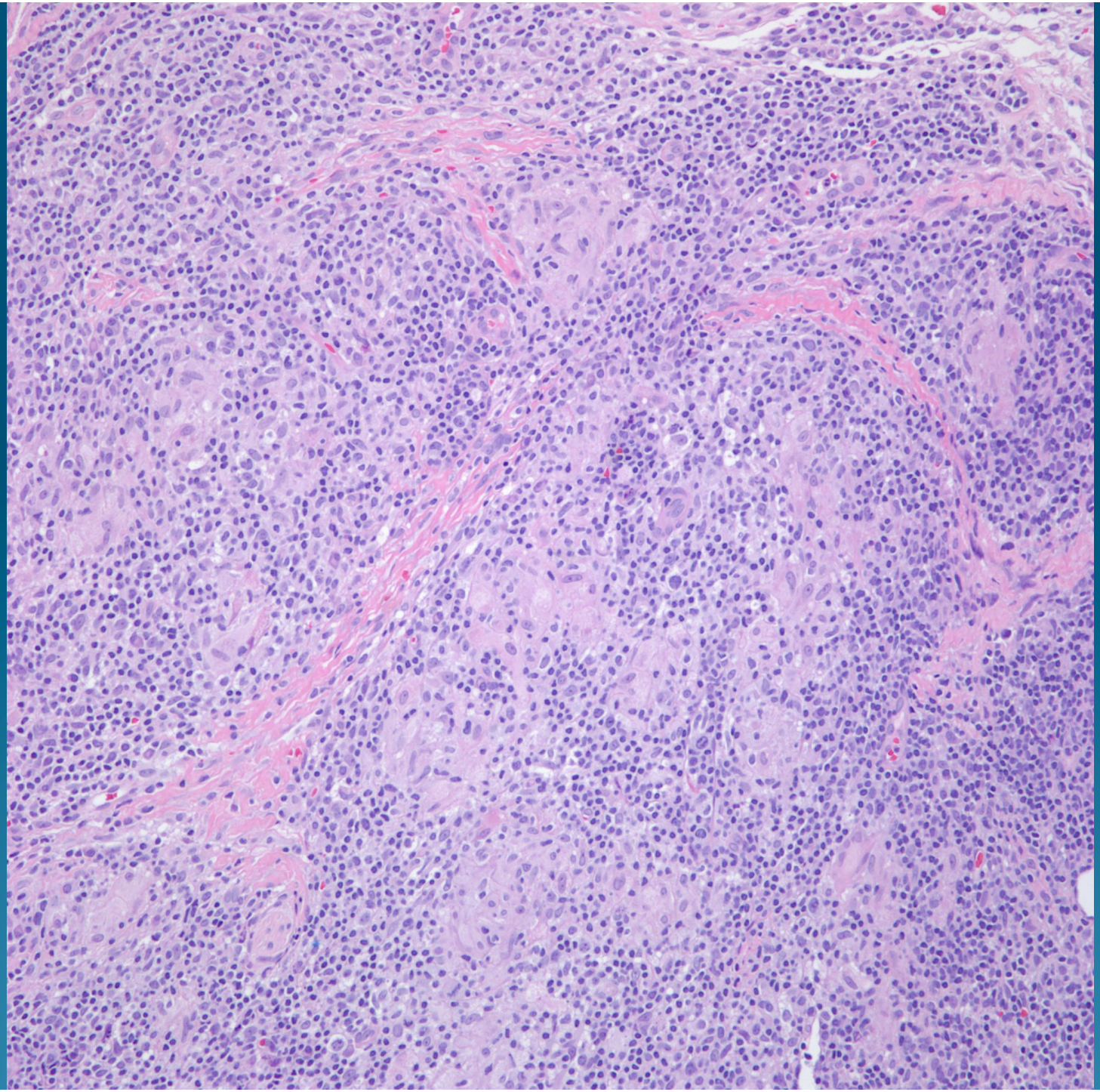

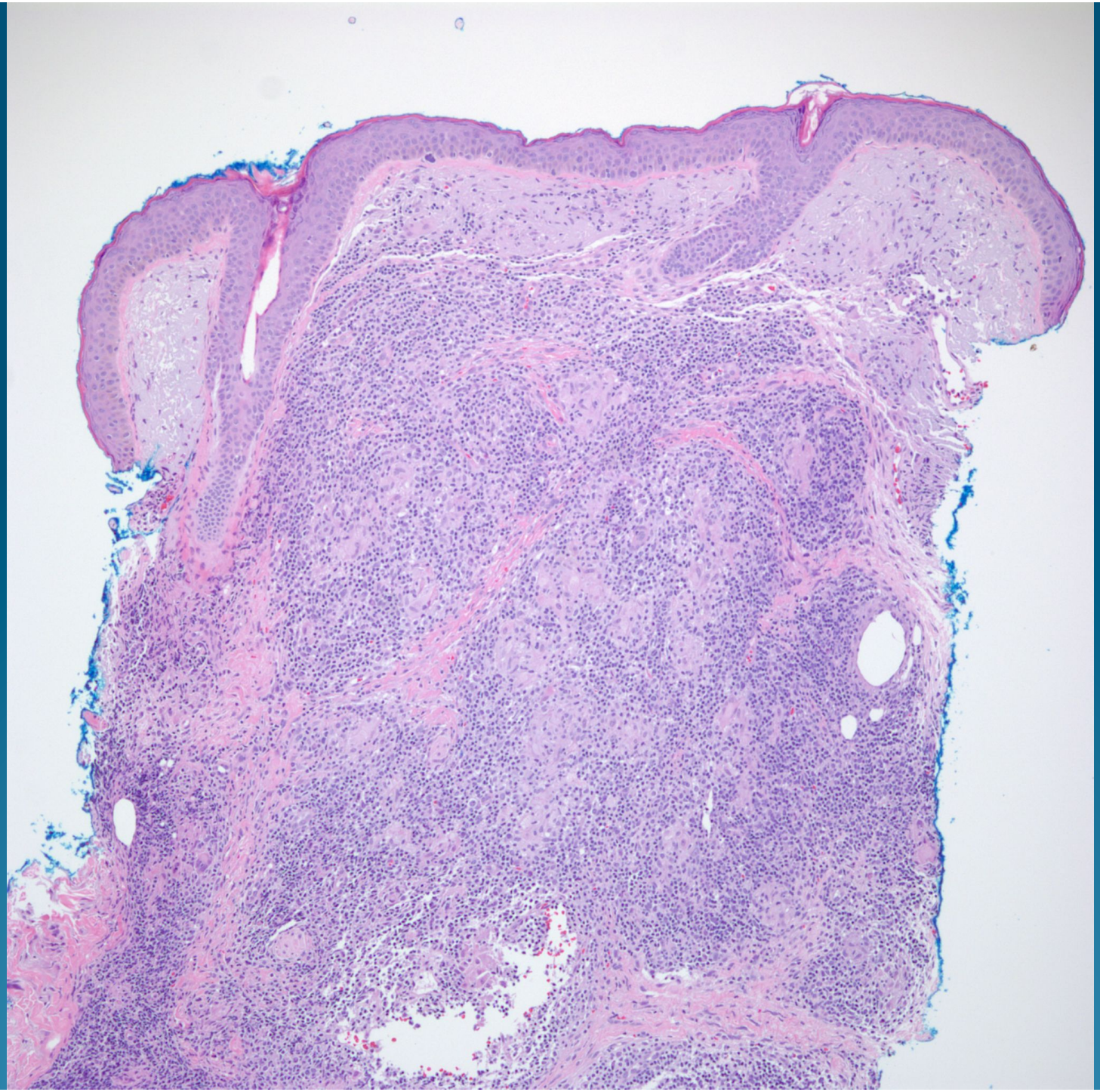

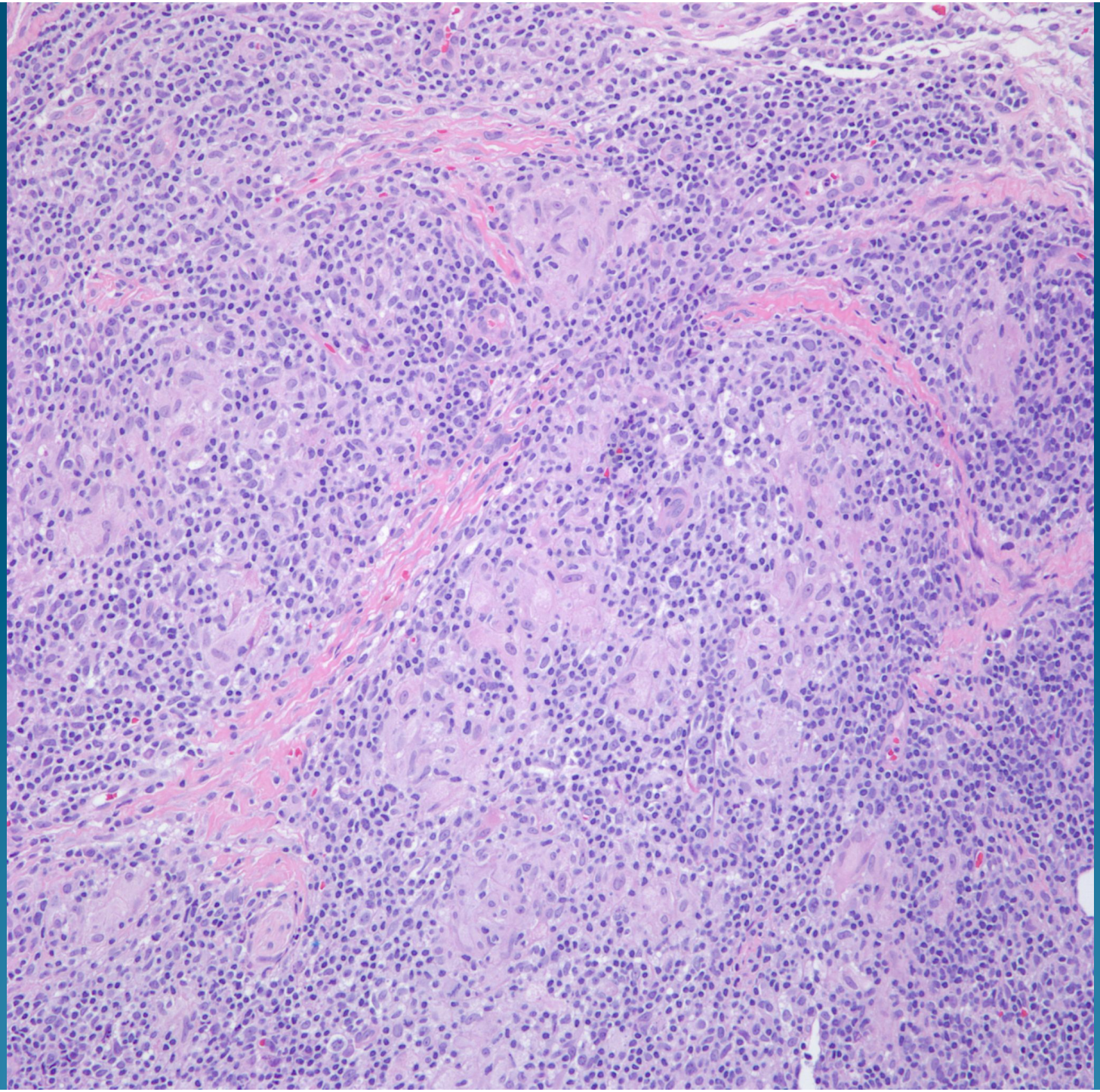

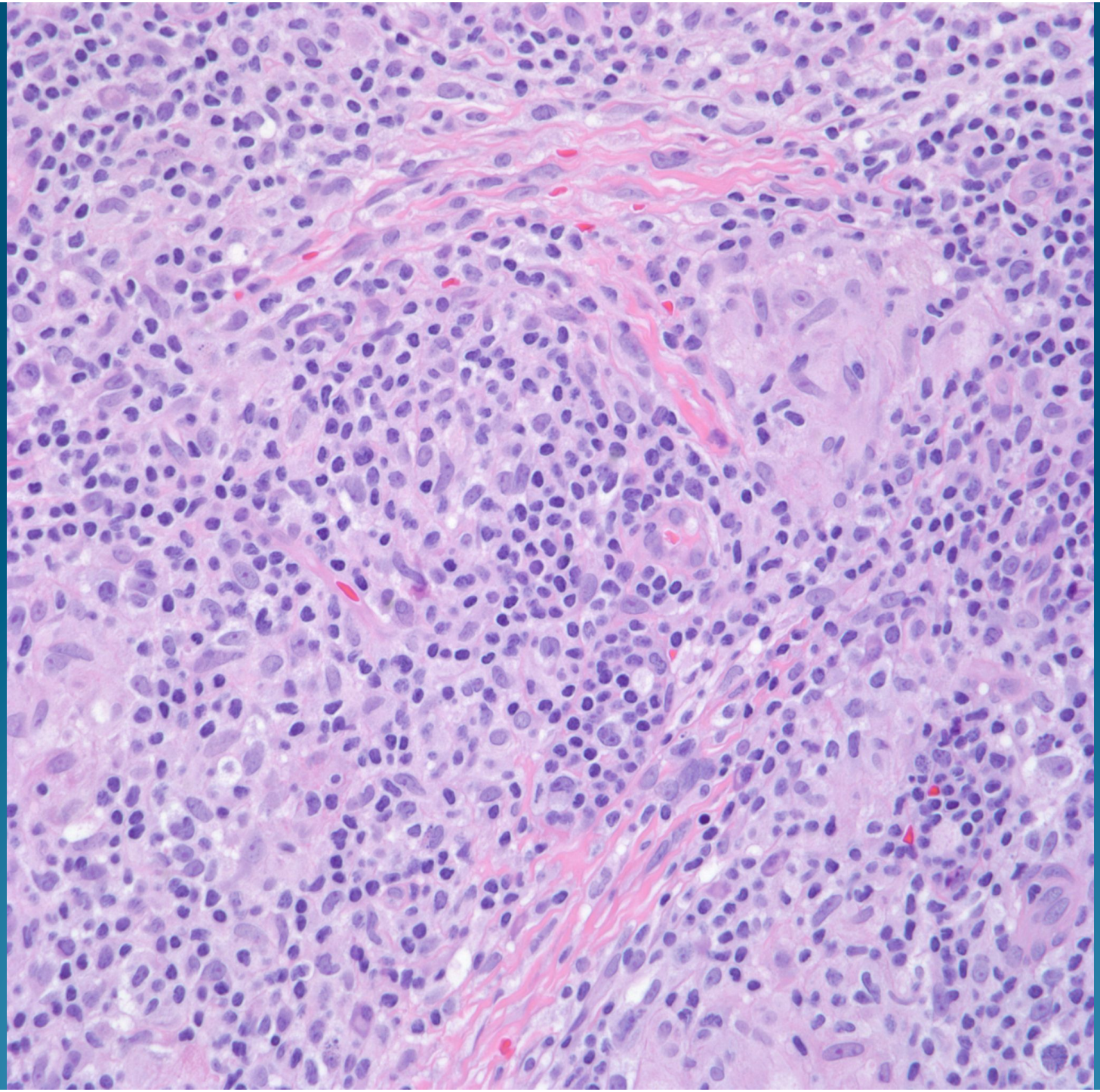

Granulomatous Rosacea

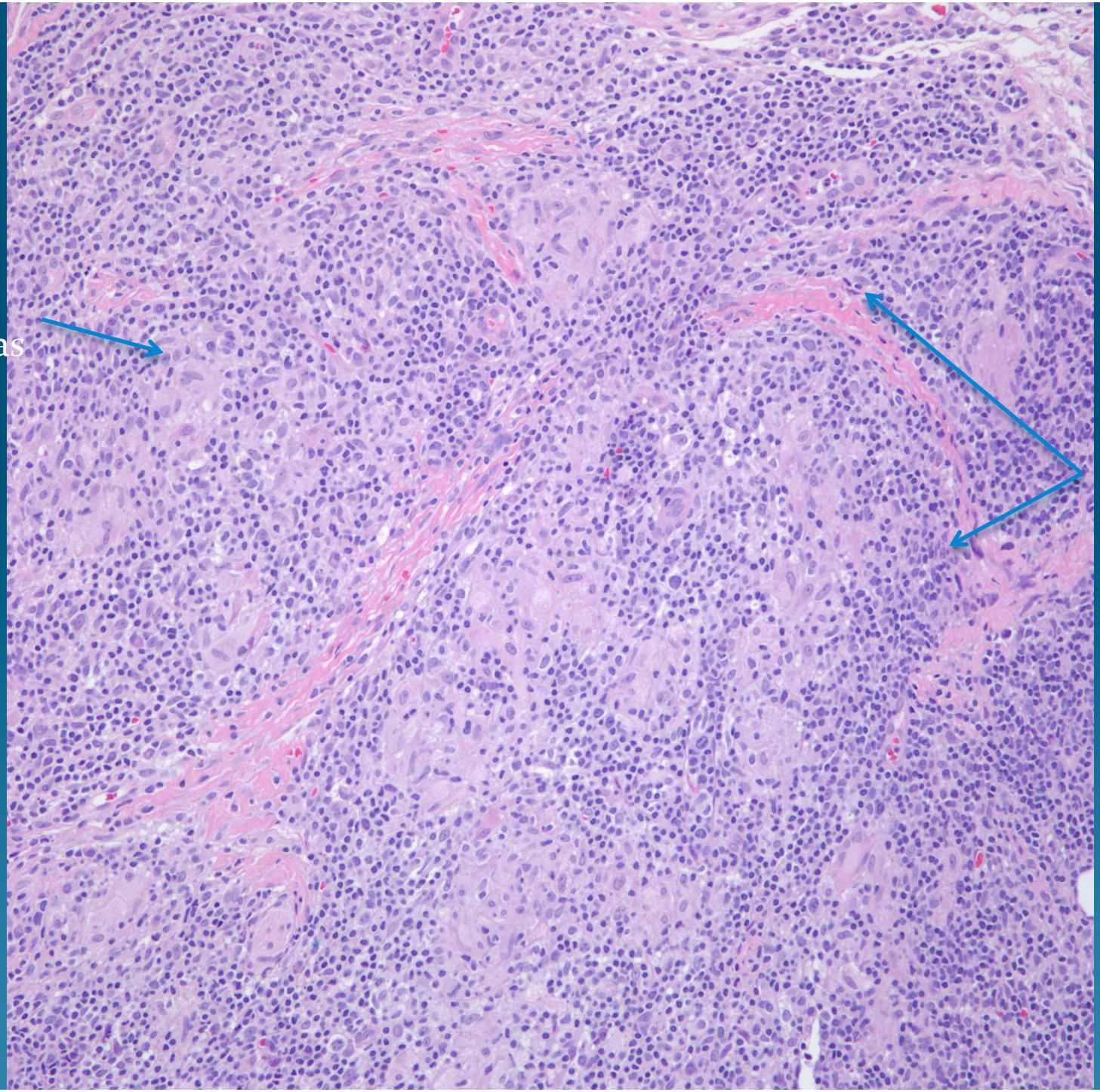
Scattered granulomas
Variable Chronic Inflam-matory cells
Rule out Infection-Get AFB, FITE, PAS

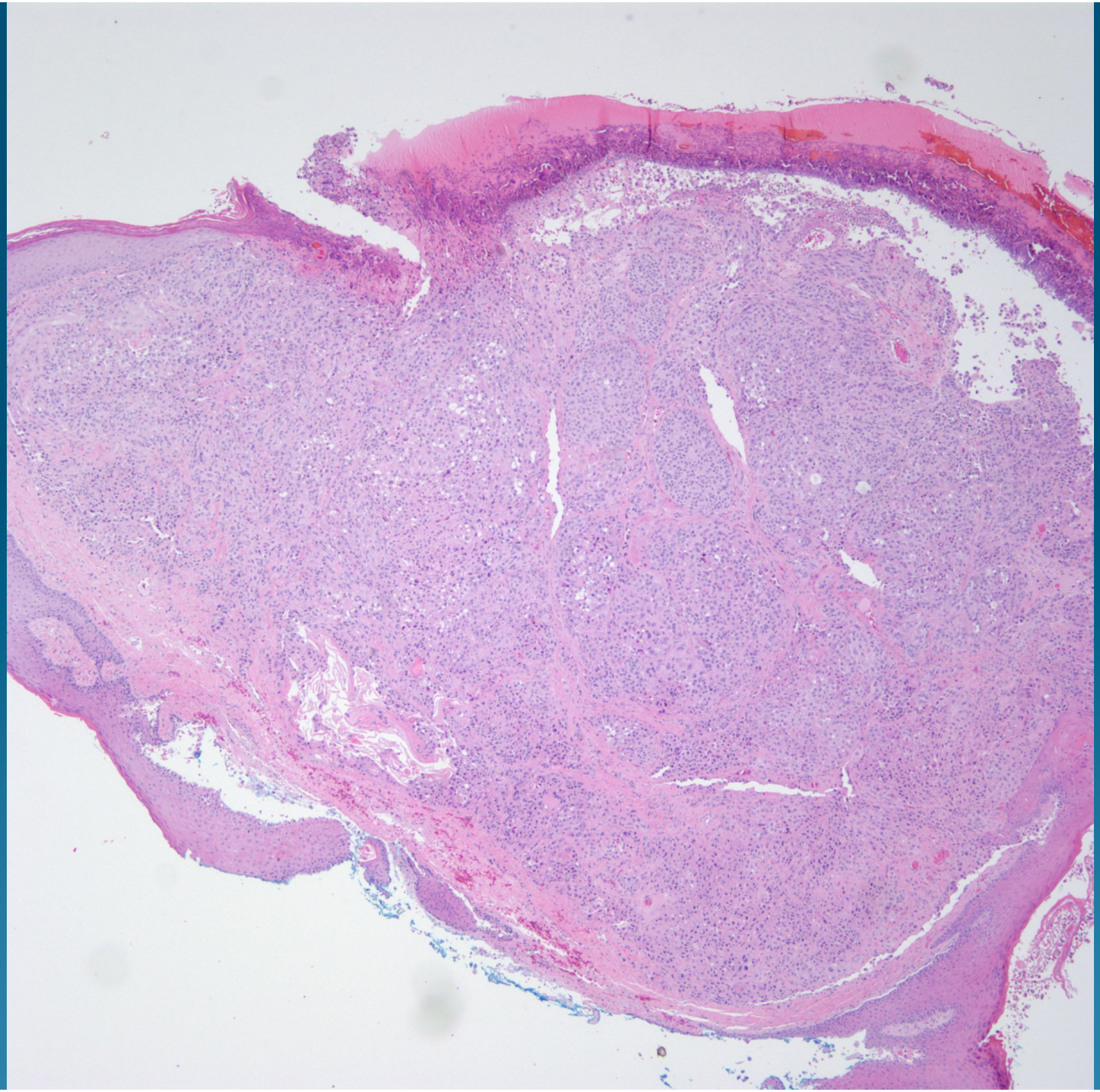

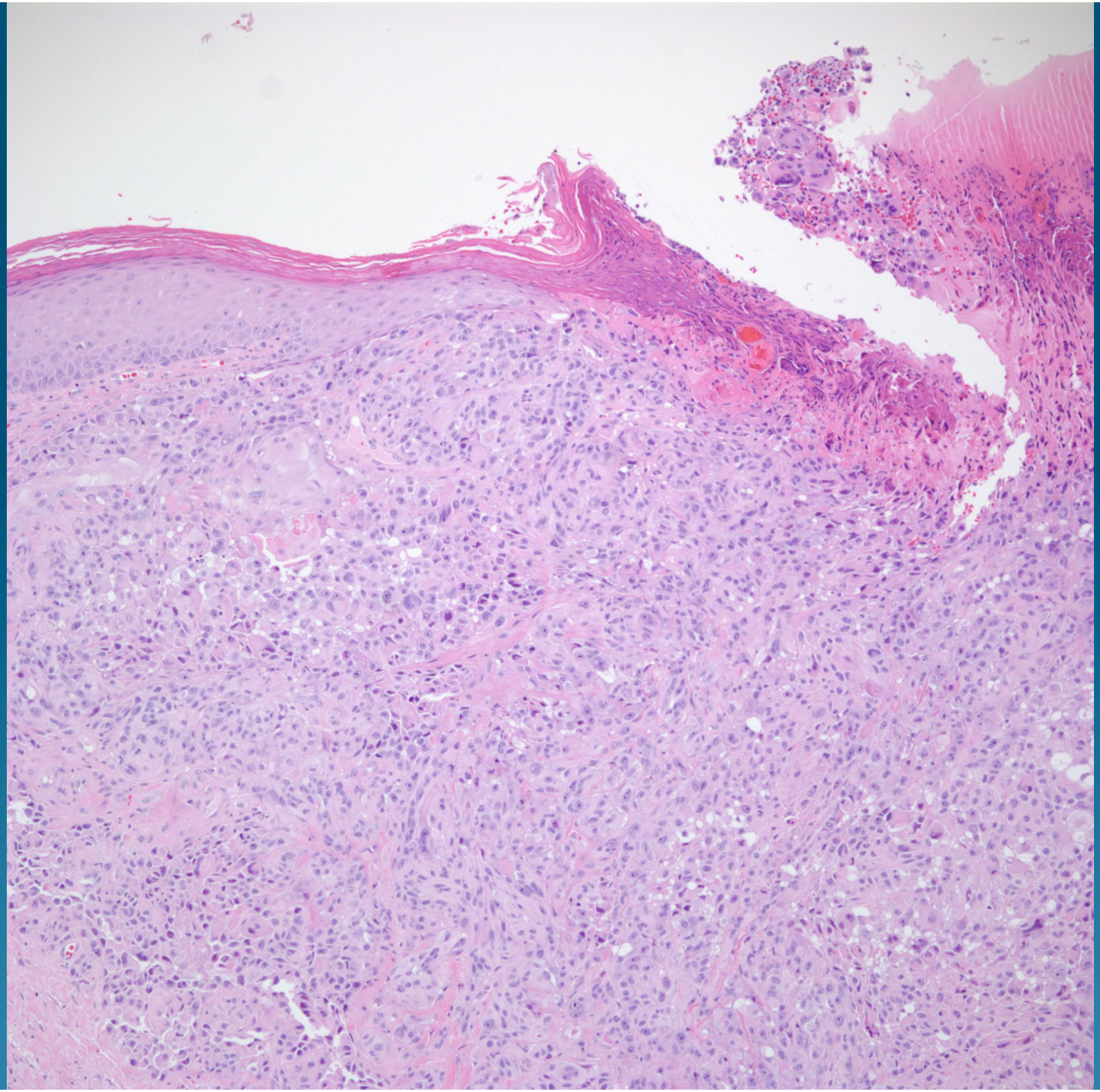

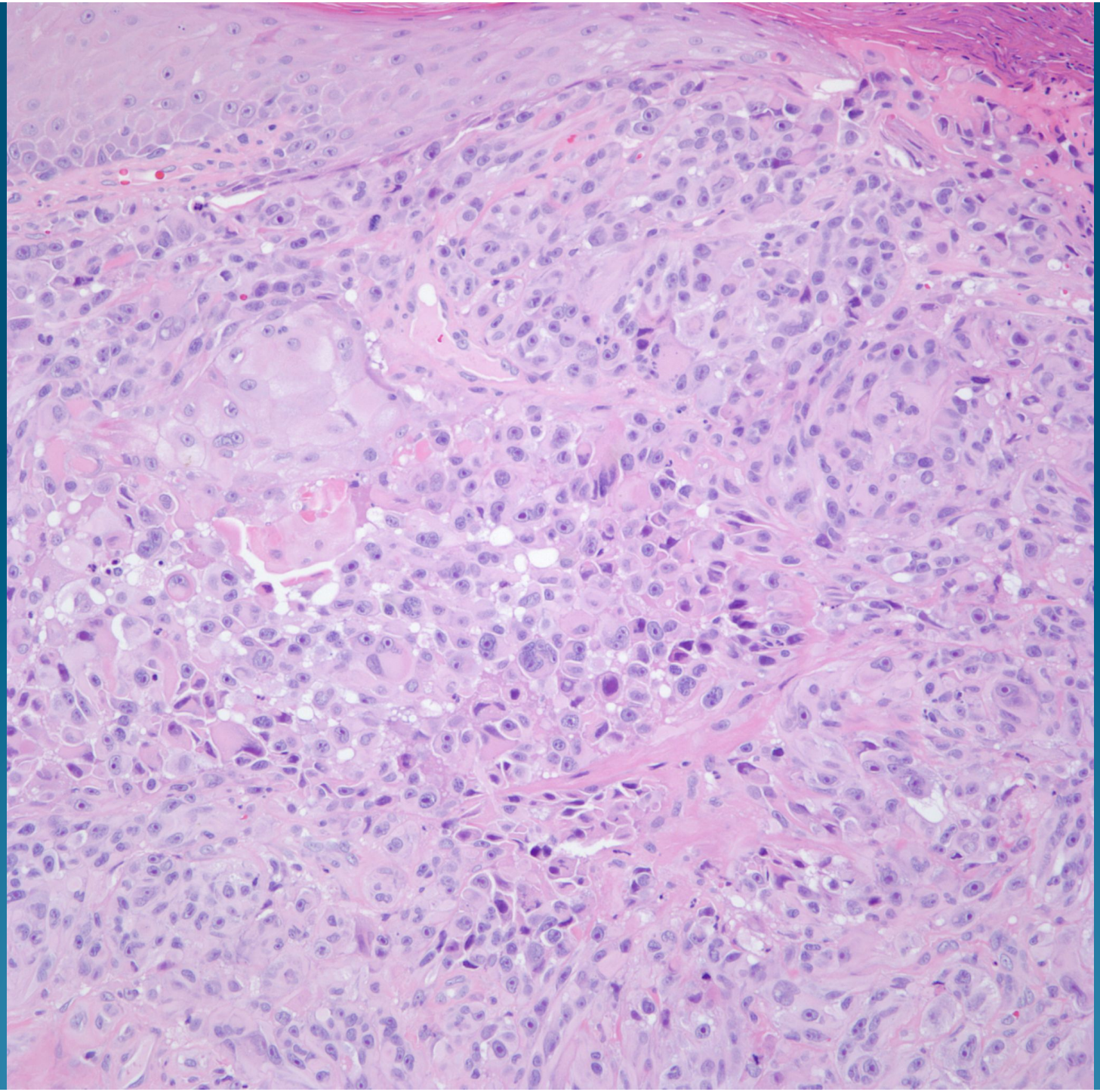

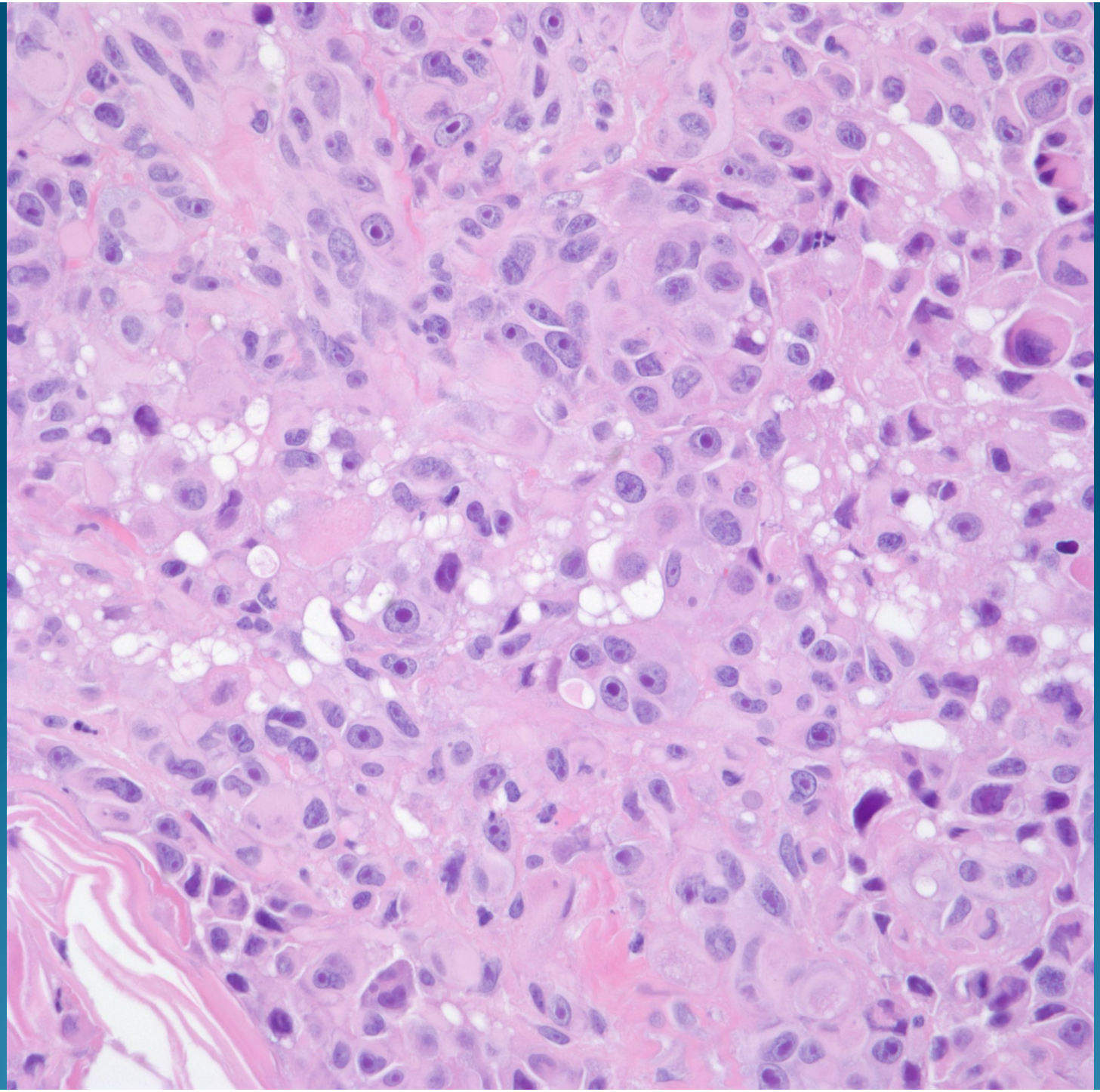

What is the best diagnosis?

A. Keratoacanthoma
B. Nodular basal cell carcinoma
C. Trichilemmoma
D. Sebaceous carcinoma
E. Pilomatricoma

Sebaceous Carcinoma

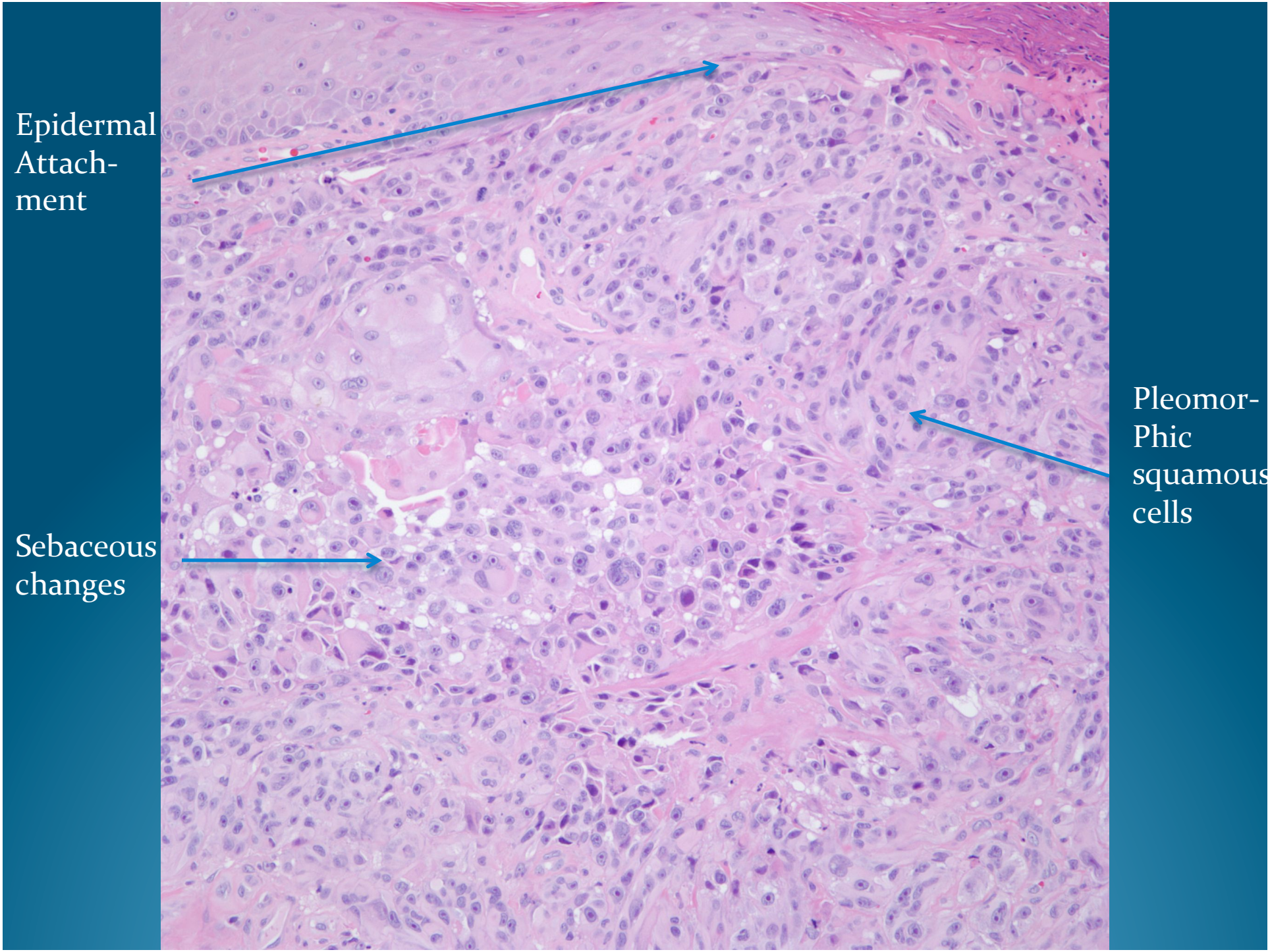
Epidermal Attach-ment
Sebaceous changes
Pleomor-Phic squamous cells

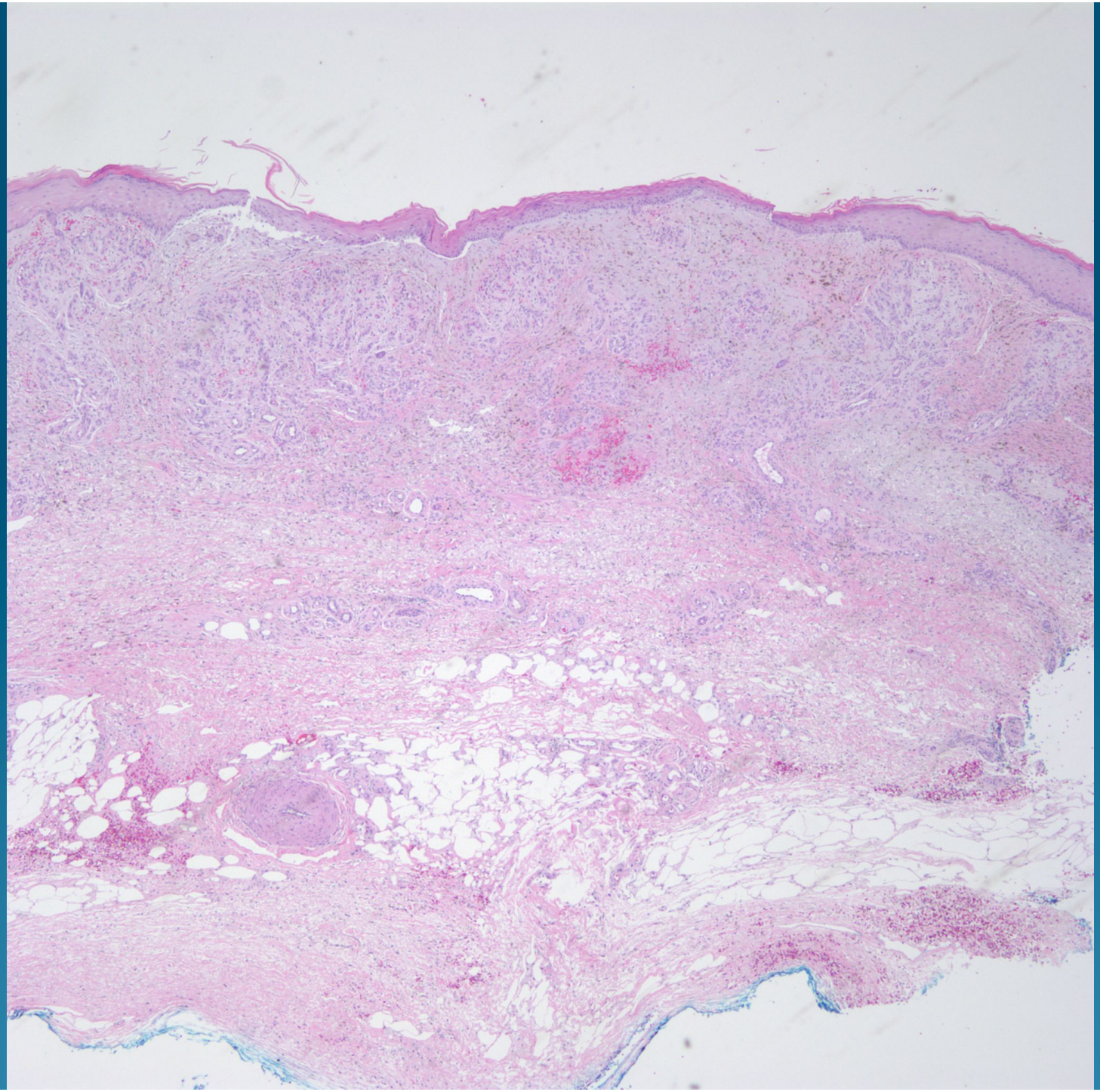

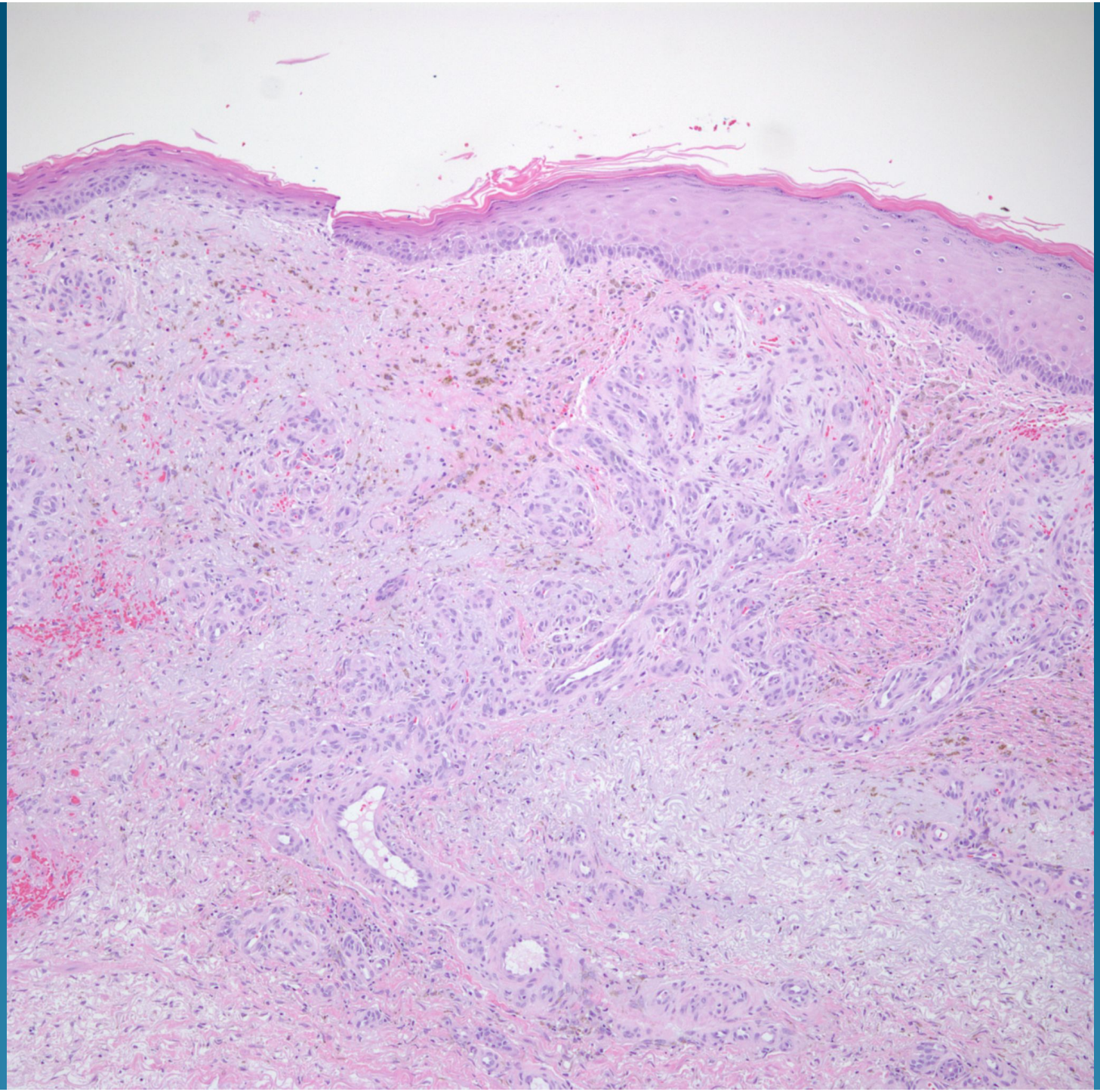

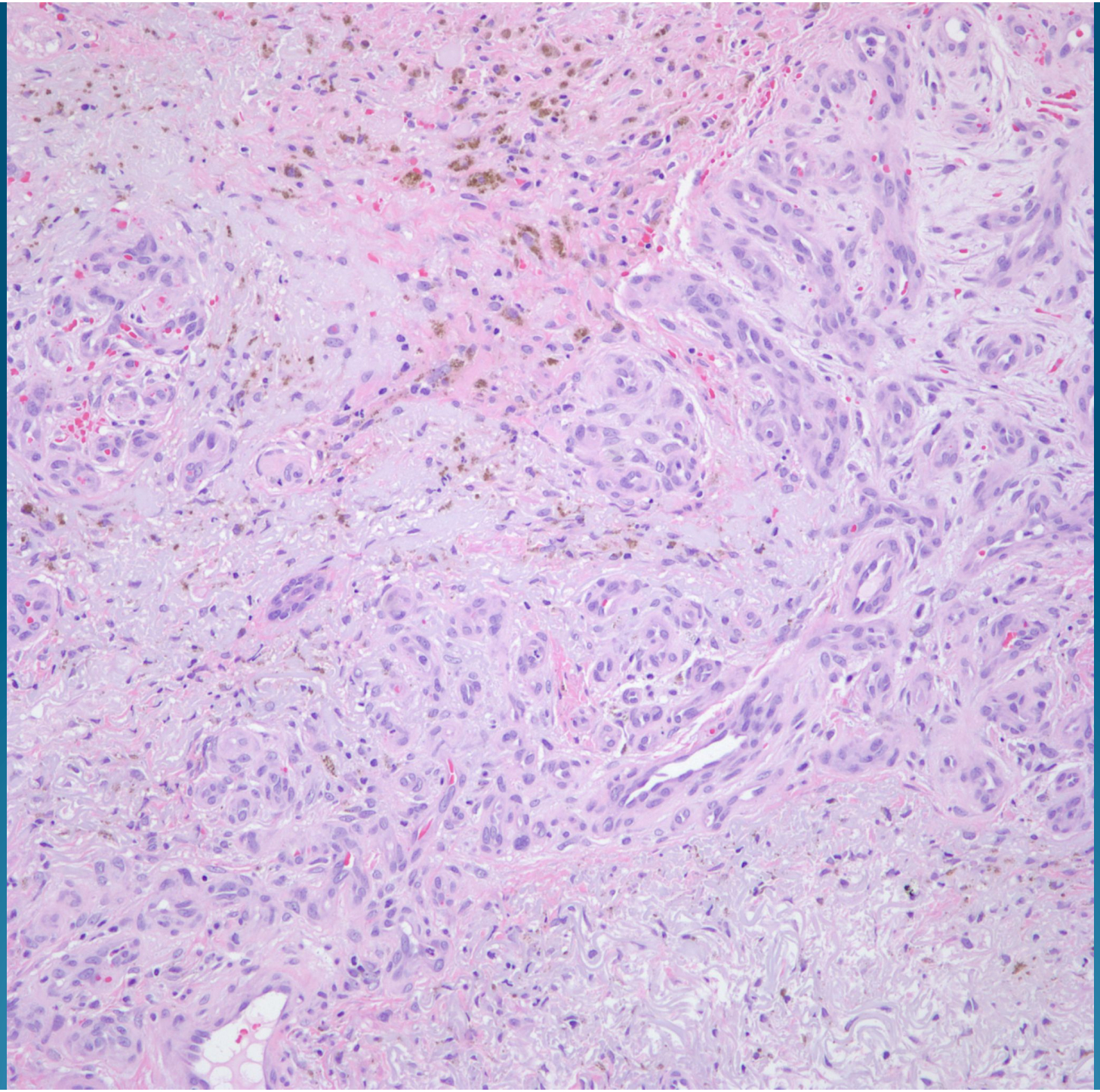

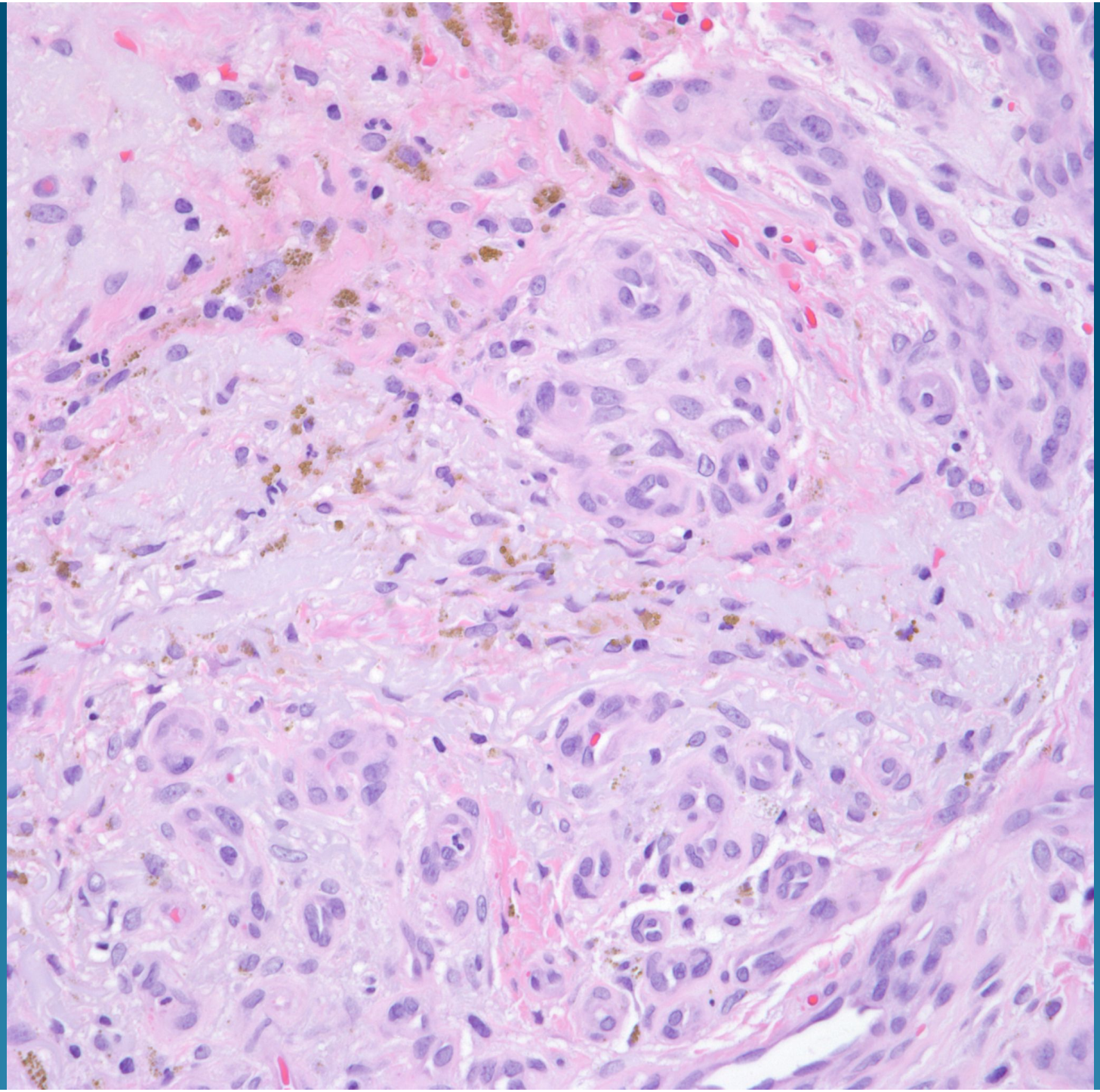

What is the best diagnosis?

A. Stasis dermatitis
B. Kaposi's sarcoma
C. Angiosarcoma
D. Papillary endothelial hyperplasia
E. Lymphangioma

Stasis dermatitis

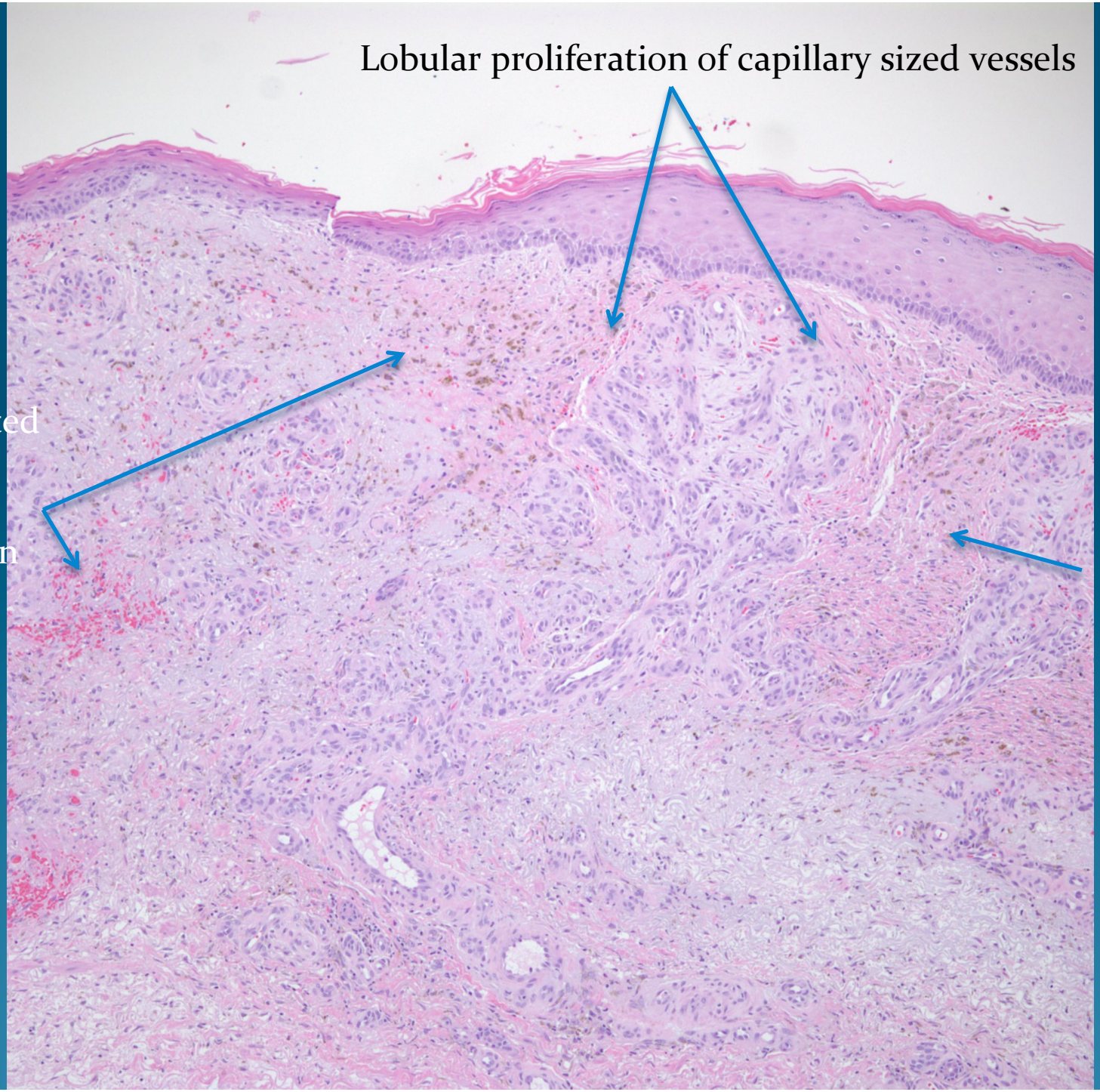
Lobular proliferation of capillary sized vessels
Extravasated rbcs with hemosi-derin laden macro-phages
Fibroplasia

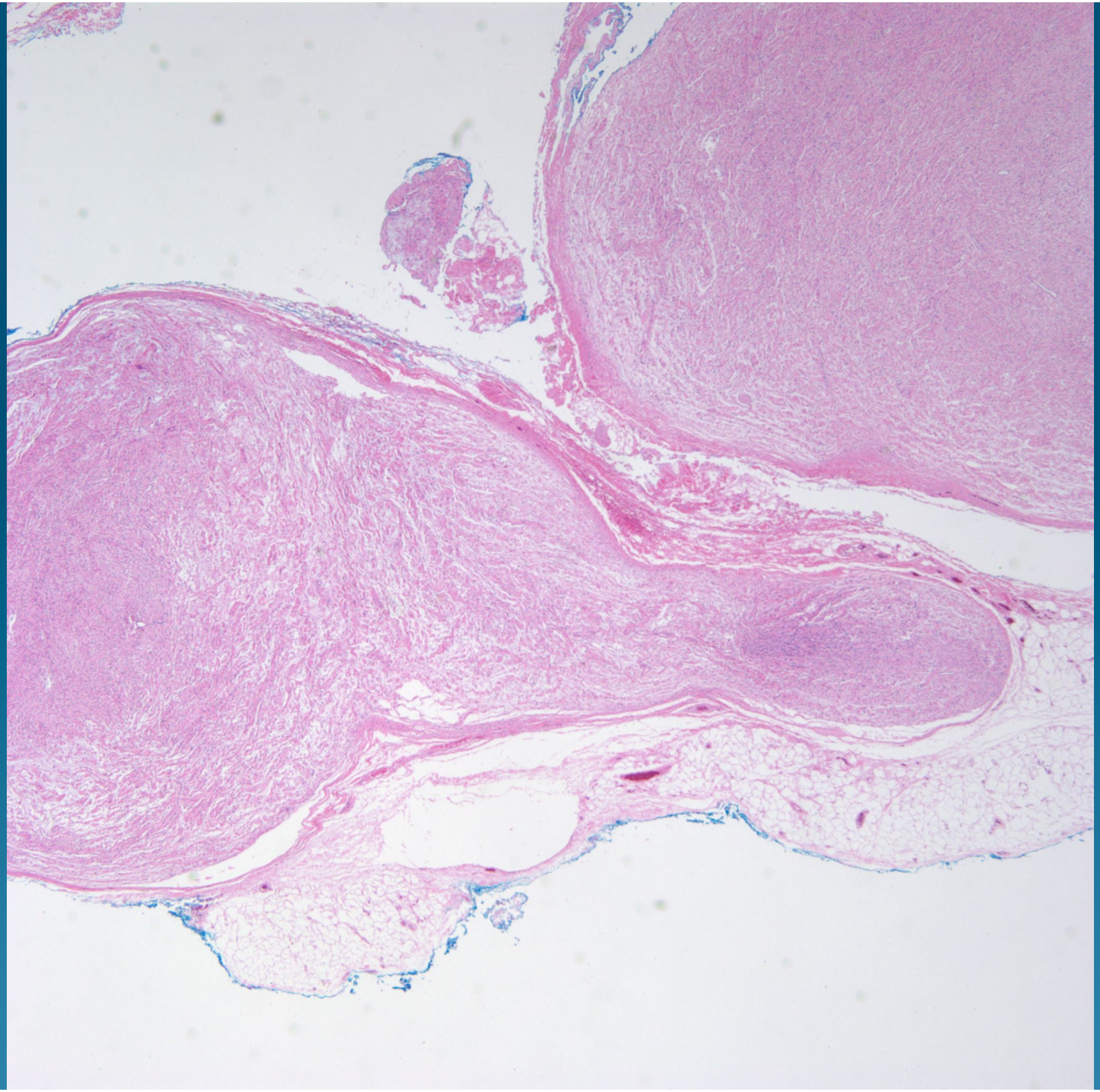

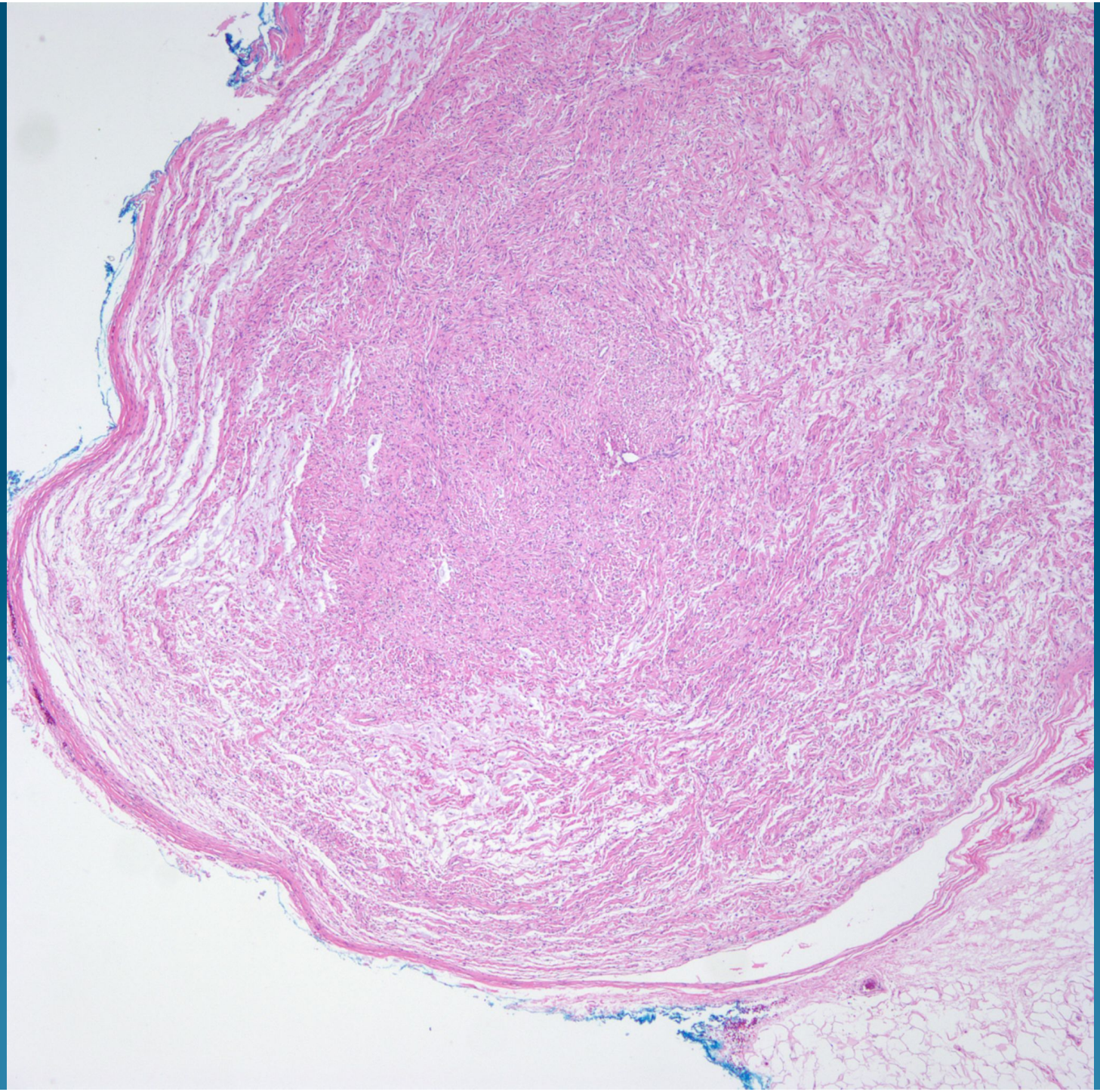

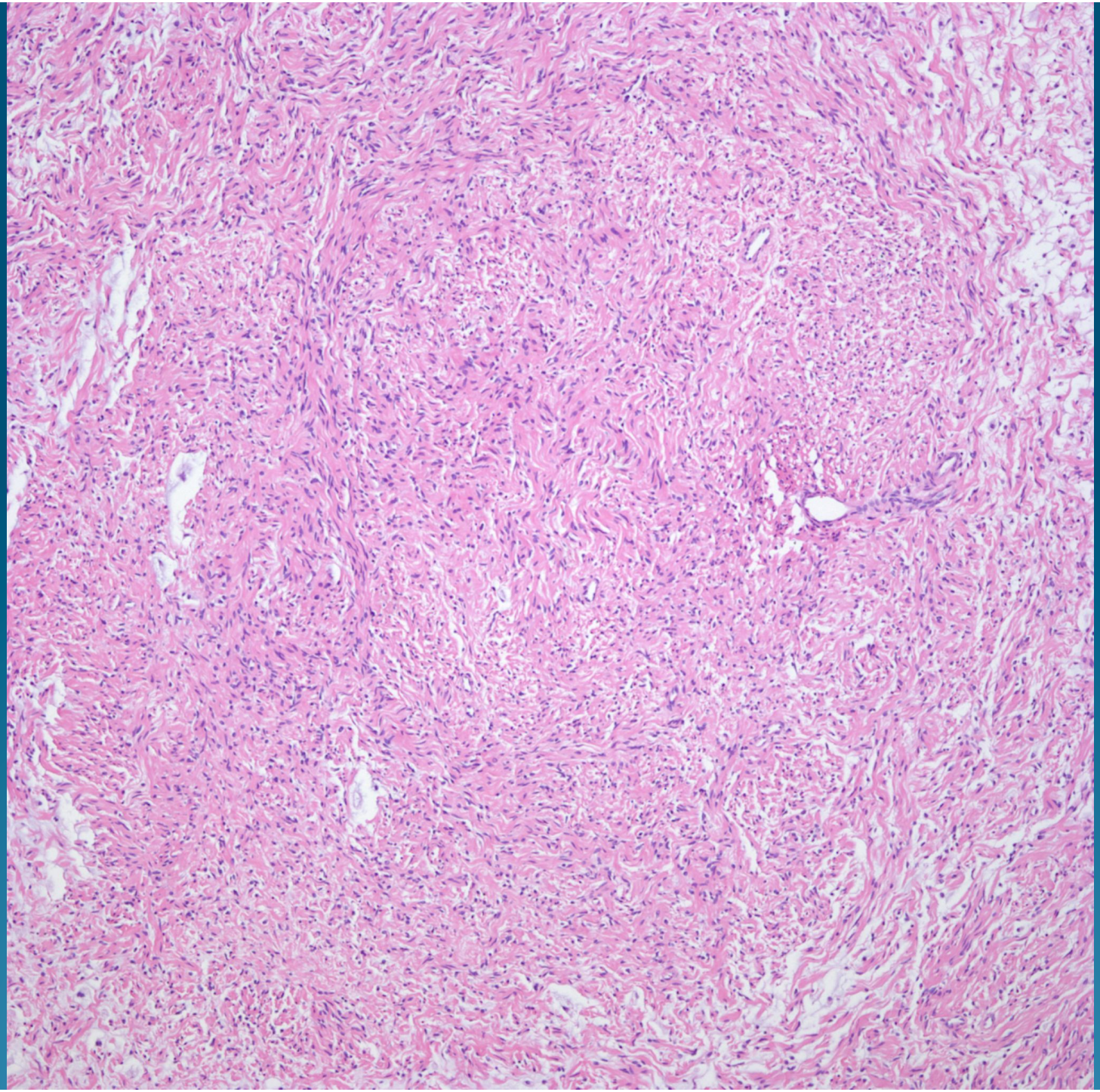

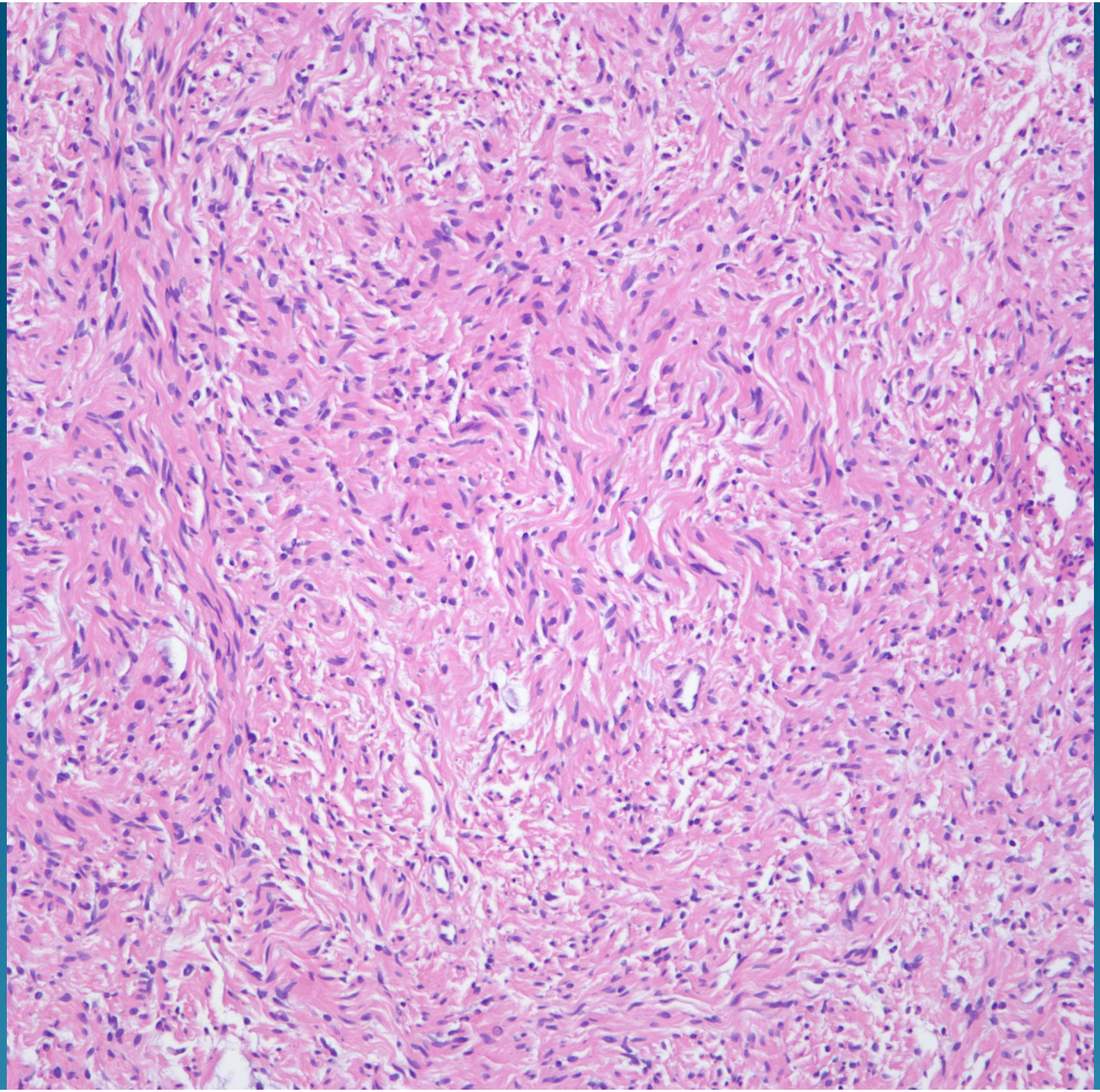

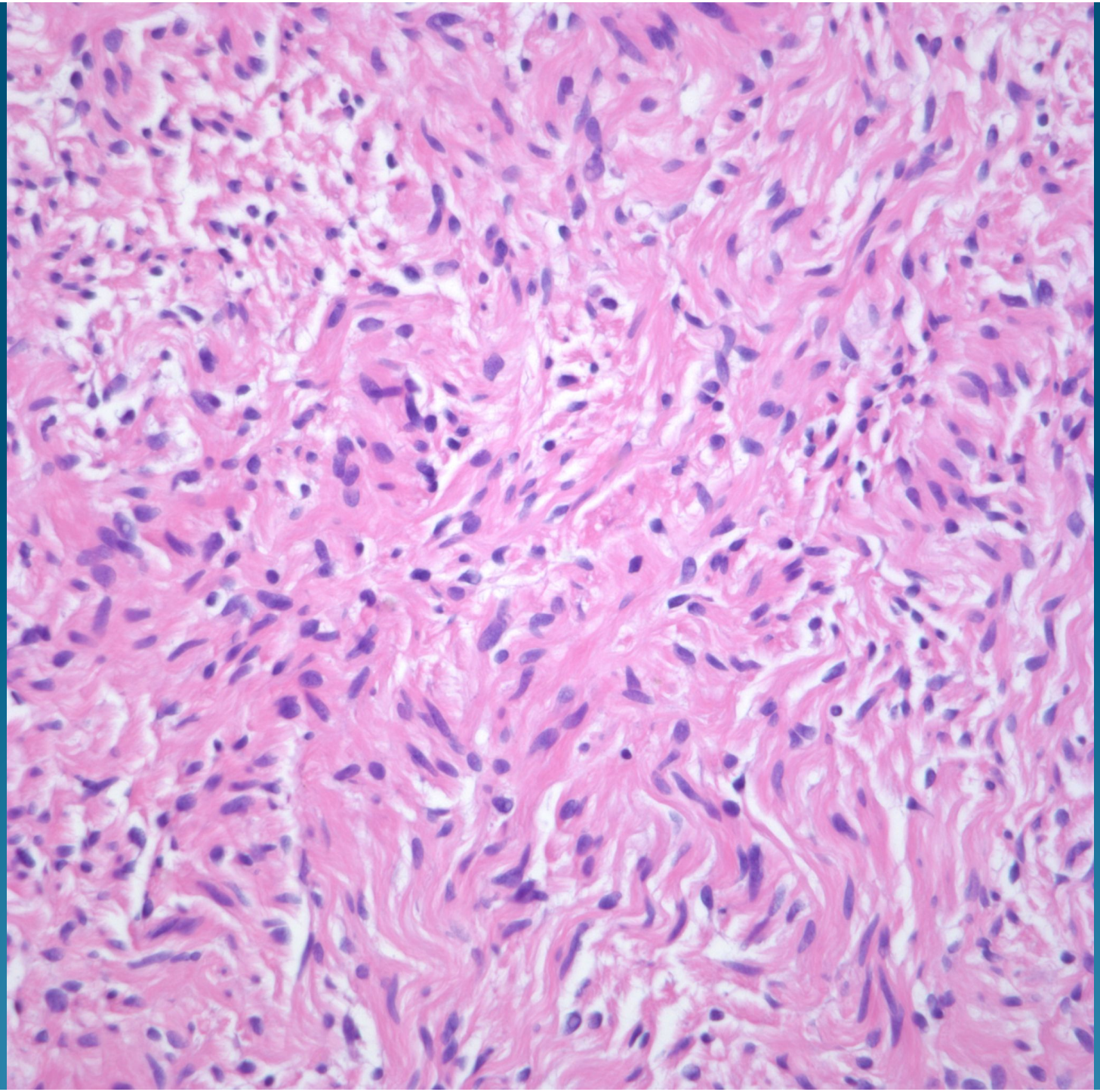

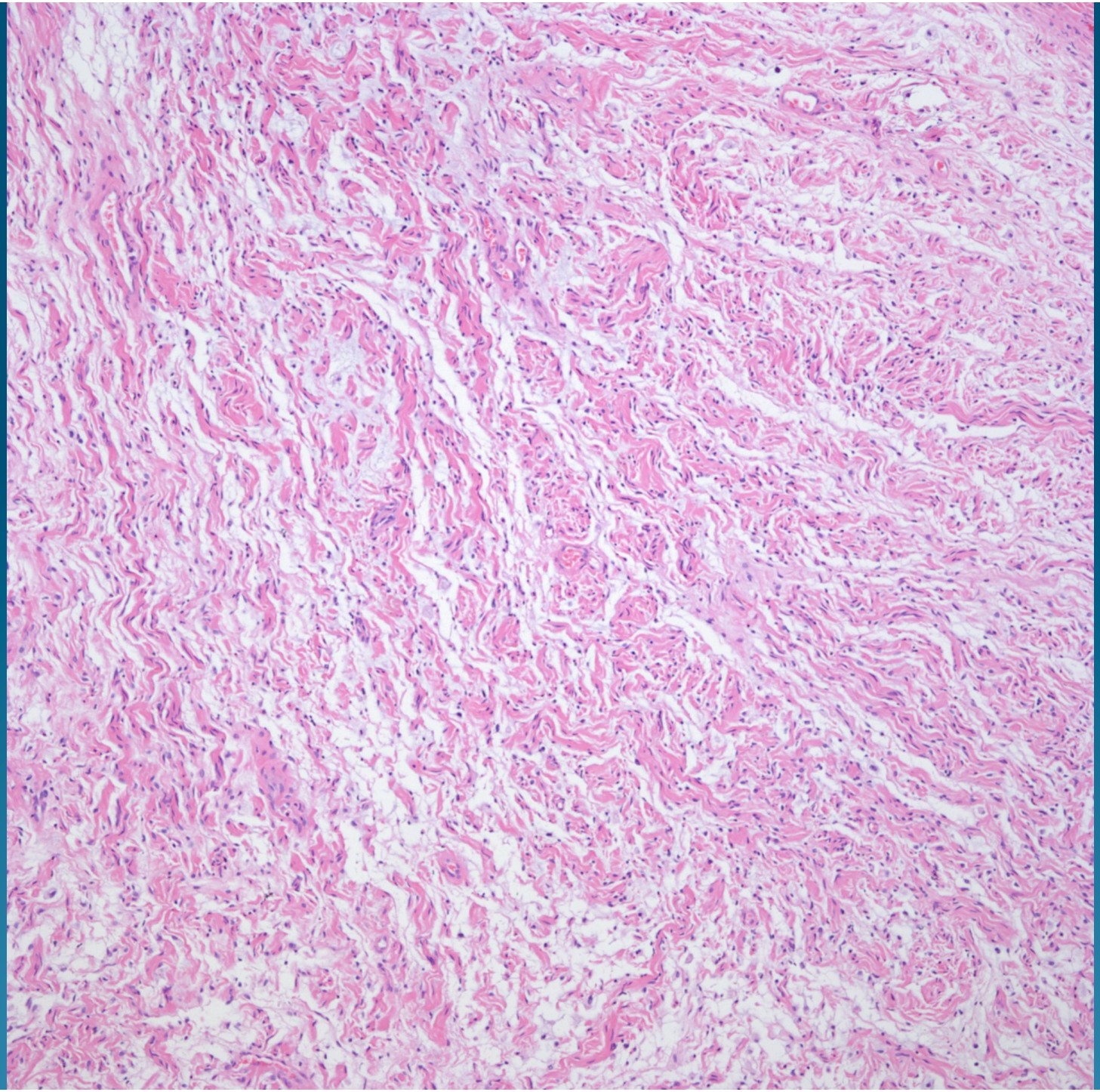

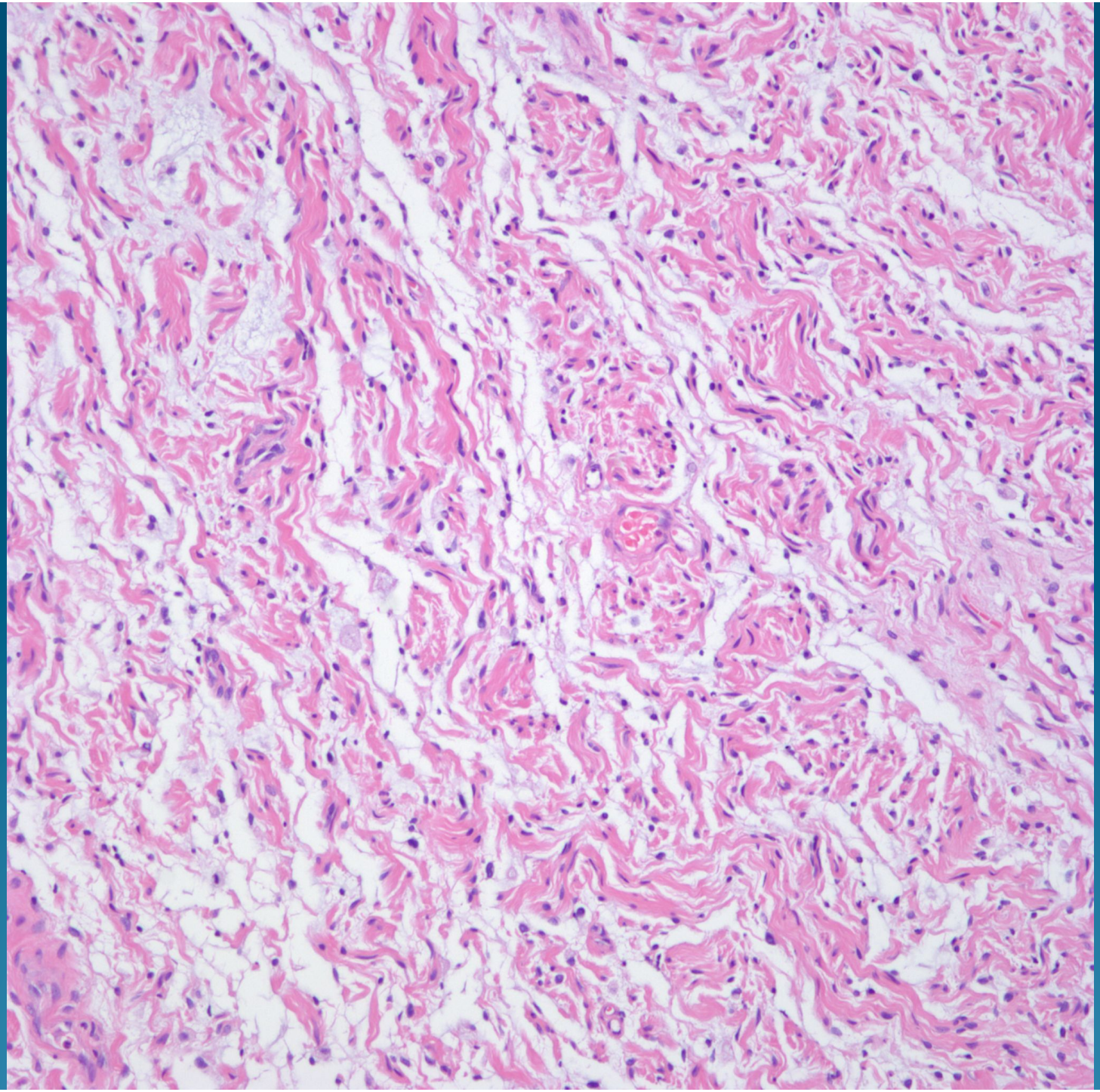

What is the best diagnosis?

A. Palisaded and encapsulated neuroma
B. Neurofibroma
C. Traumatic neuroma
D. Neurilemmoma
E. Neurothekeoma

Neurilemmoma
(Cutaneous schwannoma)

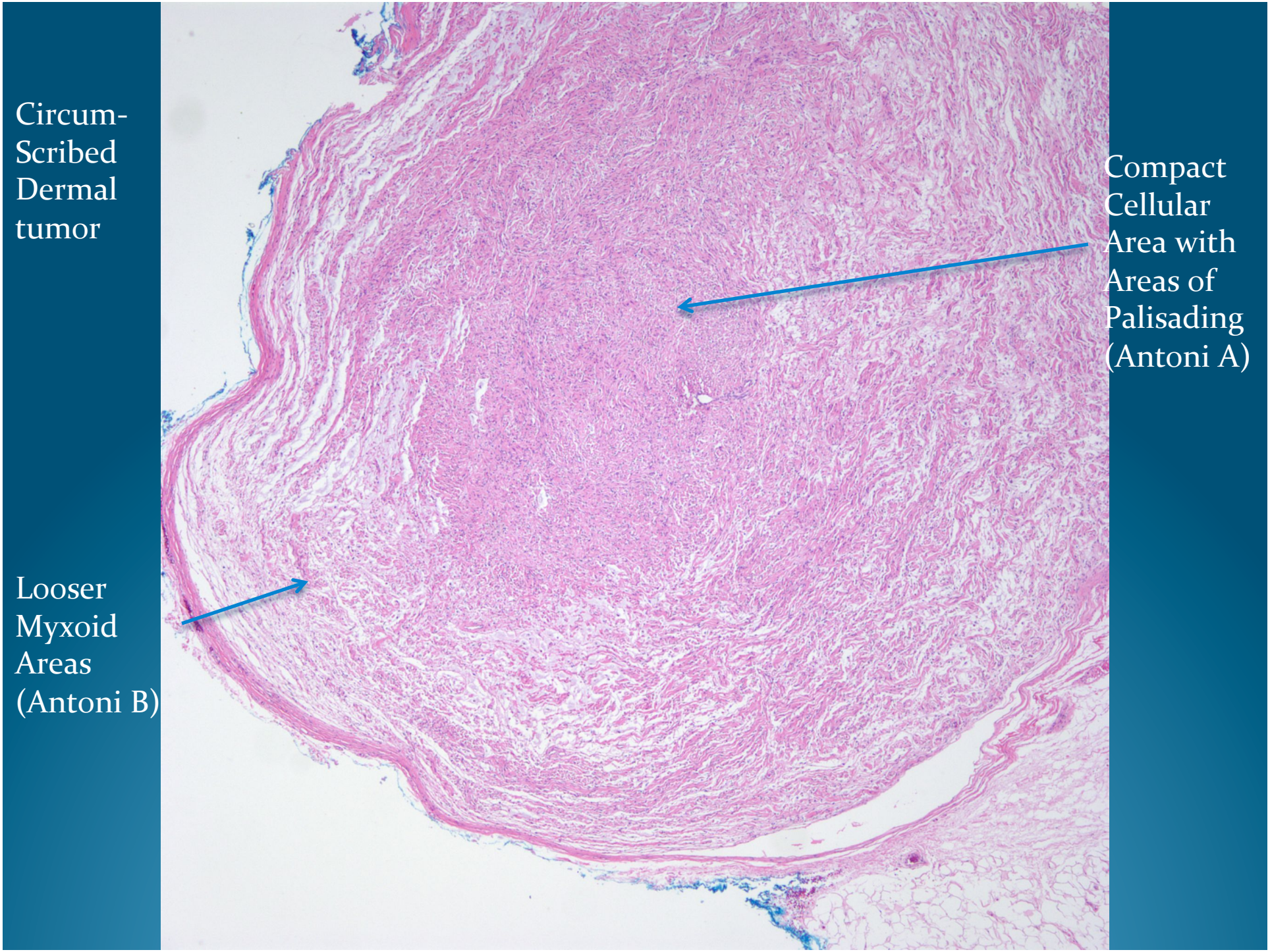
Circum-
Scribed
Dermal
tumor
Compact
Cellular
Area with
Areas of
Palisading
(Antoni A)
Looser
Myxoid
Areas
(Antoni B)

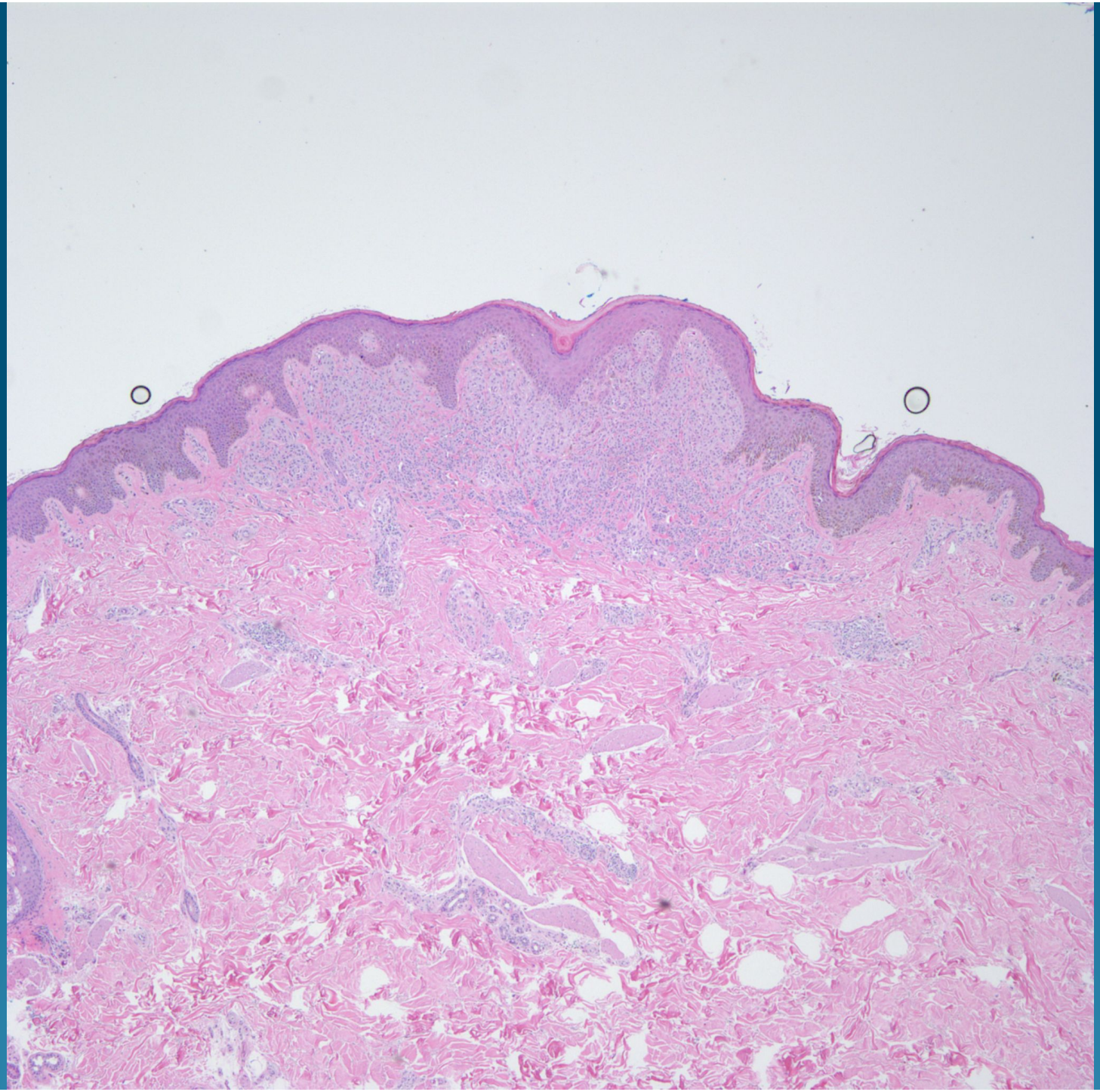

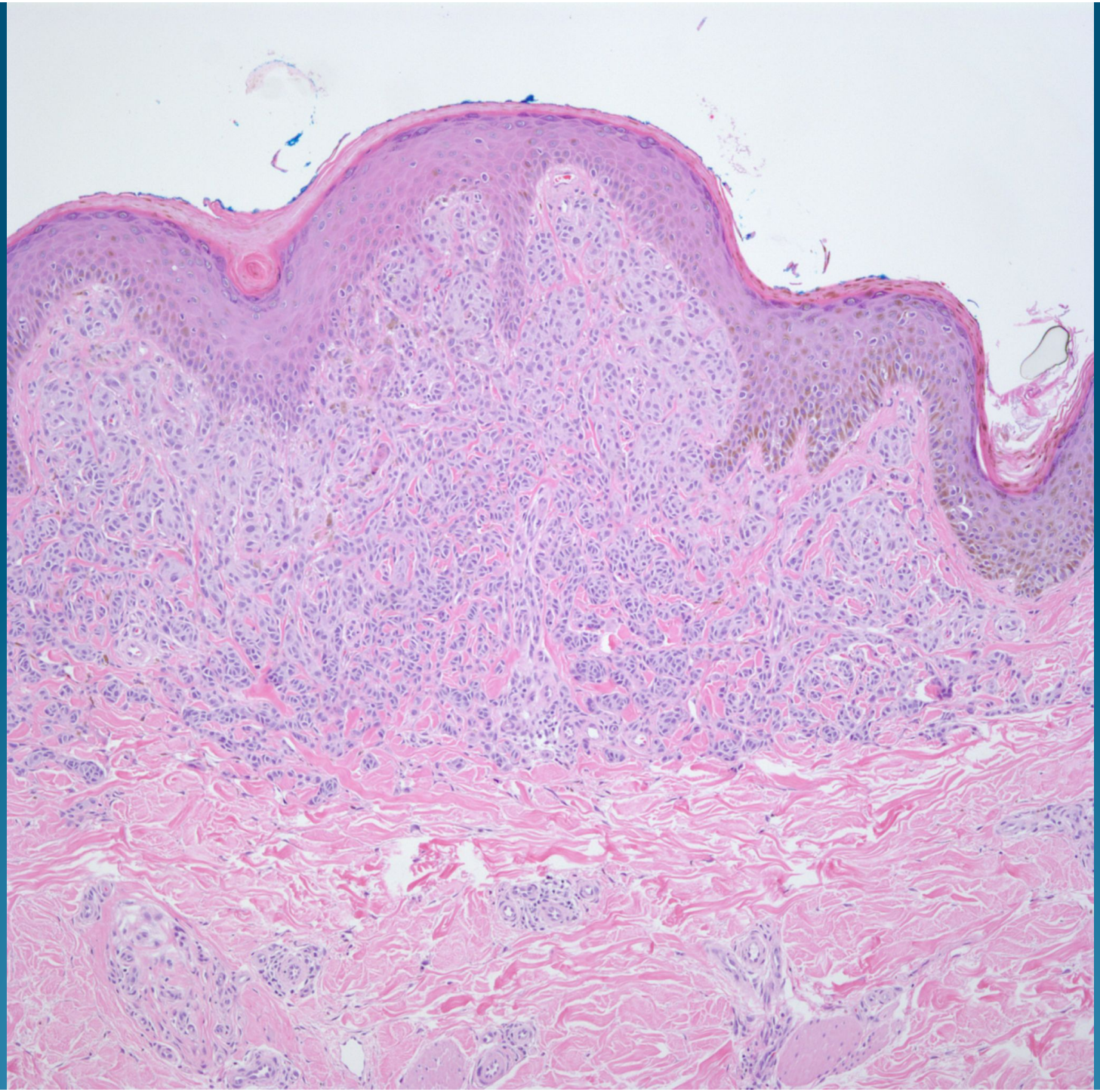

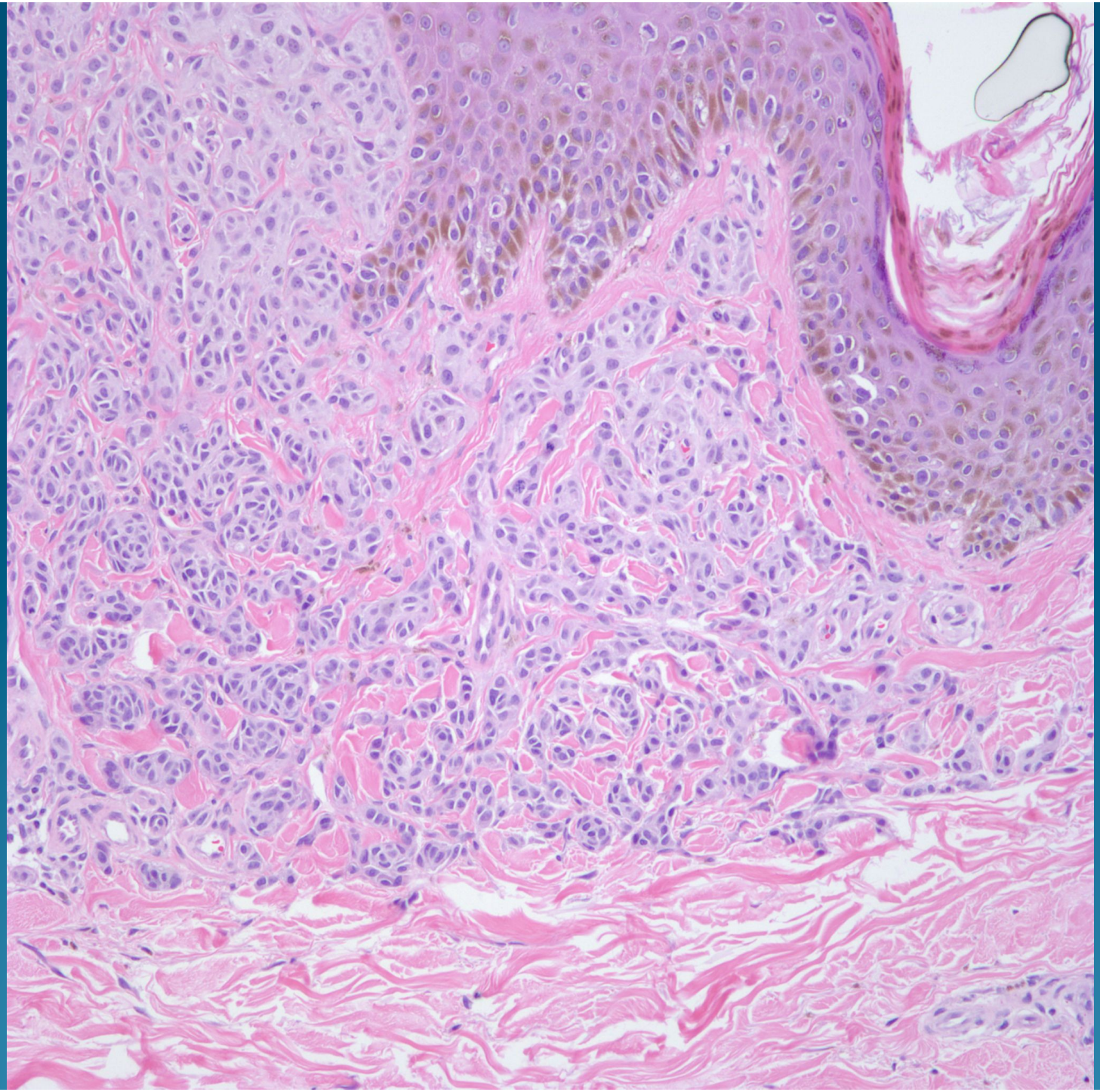

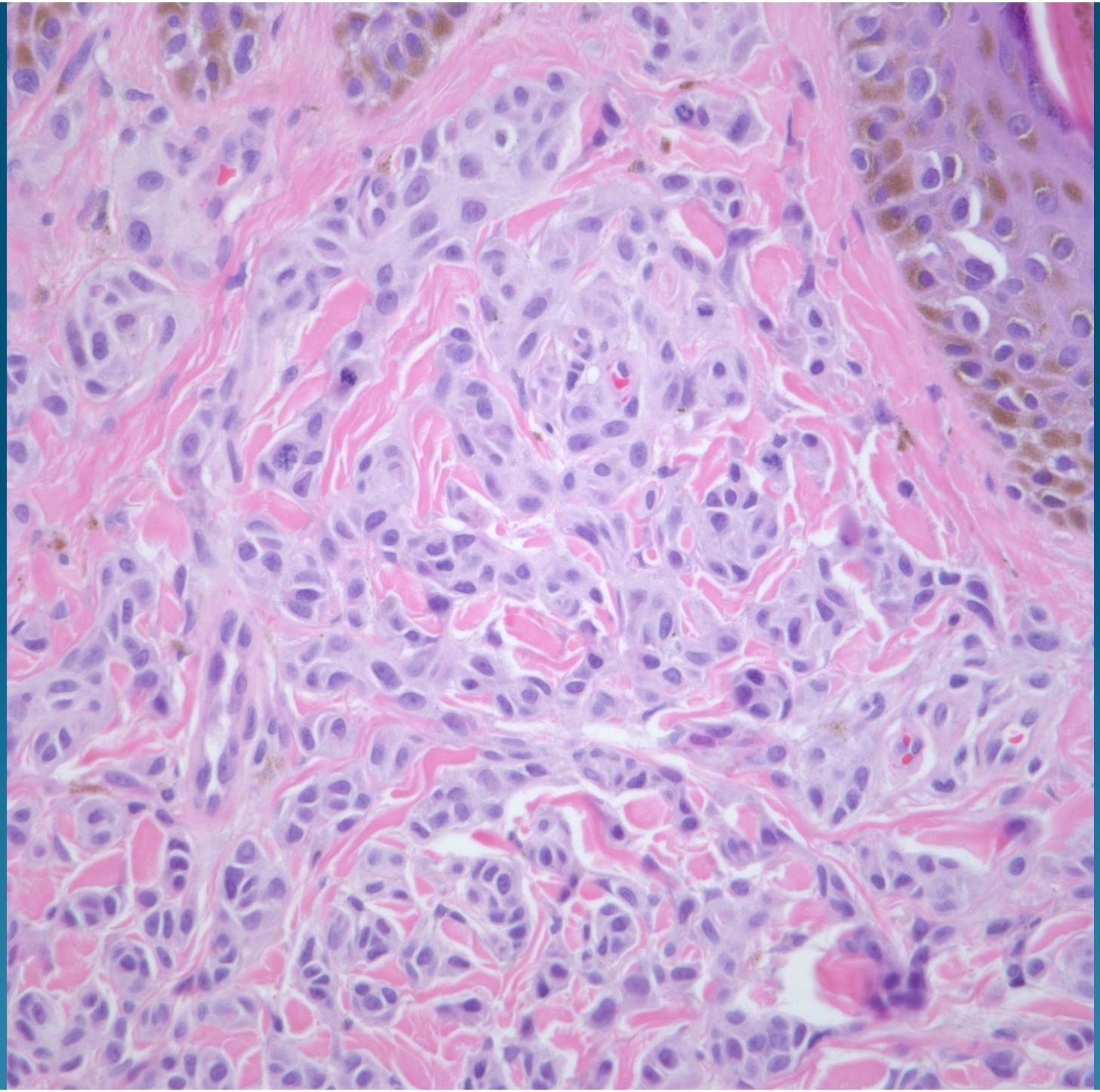

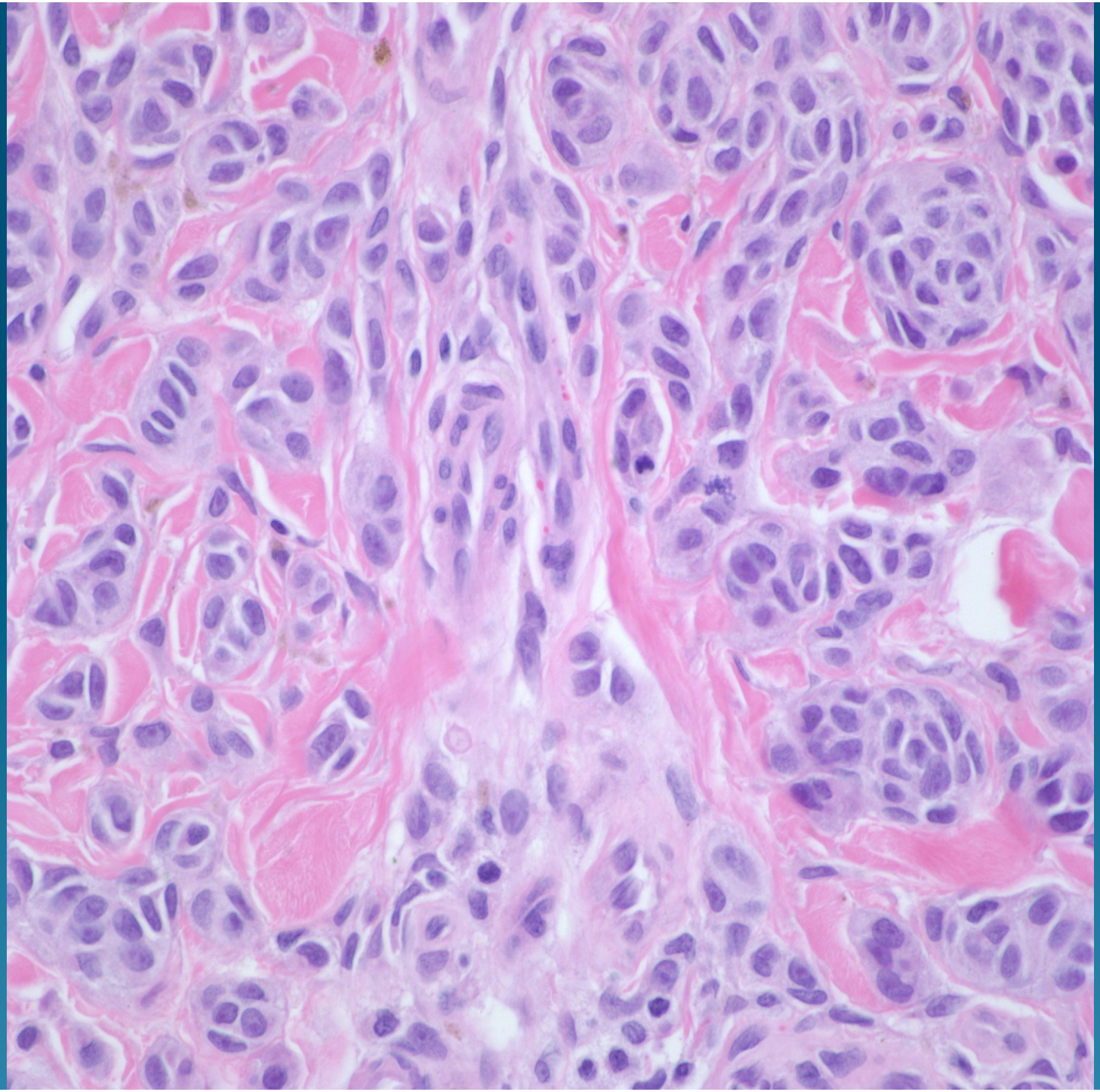

Nevoid Malignant Melanoma

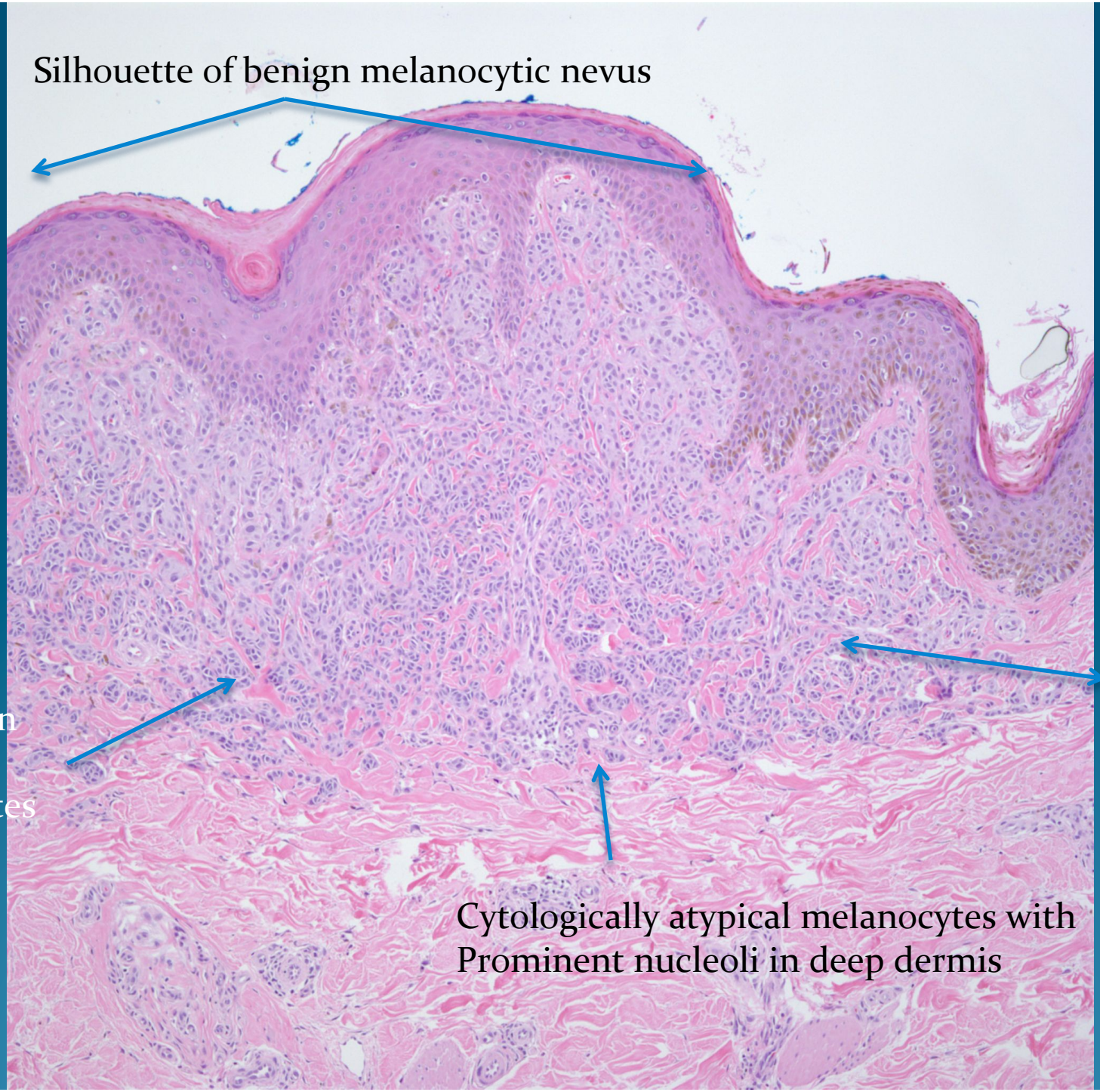
Silhouette of benign melanocytic nevus
No maturation Of melanocytes
Mitotic Figures In deep Dermal Melano-cytes
Cytologically atypical melanocytes with Prominent nucleoli in deep dermis